



## Research Article

## Total Esophagogastric Dissociation for Refractory Gastroesophageal Reflux Disease: Preliminary Experience

D'Alessandro PD\*, Rubio MA, Paz EGN, Takeda SC, Boglione MM, Barrenechea ME

### Abstract

**Background:** Neurologically impaired (NI) children frequently present with severe swallowing difficulties and gastroesophageal reflux disease (GERD), leading to recurrent aspiration and failure to thrive. While Nissen fundoplication is the standard treatment, it carries a high risk of recurrence in this population due to gastric dysmotility and spasticity. Total esophagogastric dissociation (TEGD) is a definitive surgical alternative for redo cases or primary treatment in selected patients where anti-reflux failure significantly impacts quality of life.

**Aims:** To describe our initial institutional experience with TEGD, reporting surgical outcomes, early and late complications, and preliminary qualitative observations regarding postoperative quality of life in a complex pediatric cohort.

**Methods:** A retrospective observational review was conducted using an institutional REDCap database (2007–2023). All patients undergoing TEGD were included without exclusion criteria. Data on demographics, primary diagnosis, surgical history, and complications were analyzed. Postoperative quality of life was assessed through structured caregiver interviews focused on respiratory events, vomiting, and feeding habits. Due to the small sample size, a descriptive analysis was performed to avoid Type II statistical errors.

**Results:** Eighteen children (11 male, 7 female) underwent TEGD, with 66.7% presenting severe neurological impairment. Six procedures were primary and twelve were secondary "rescue" cases. Early complications (within 30 days) occurred in 33.3% of patients (n=6), with 83% requiring surgical revision for issues such as bowel obstruction or anastomotic leakage. Late complications affected 16.6% (n=3), all requiring surgery. The overall mortality rate was 11% (n=2), with only one death directly related to a late surgical complication (small bowel volvulus). Despite the morbidity, all caregivers reported an improvement in quality of life due to the resolution of GERD and a reduction in major respiratory events and vomiting. Improvements in feeding efficiency and weight gain were also consistently noted.

**Conclusion:** TEGD provides a definitive anatomical barrier against reflux in complex pediatric patients when traditional methods fail. Although associated with a significant complication rate and a demanding learning curve, it offers high clinical success and improved well-being for NI children. Comprehensive preoperative counseling is essential for families considering this procedure.

**Keywords:** Total Esophagogastric Dissociation (TEGD); Neurologically Impaired (NI) Children; Refractory Gastroesophageal Reflux (GERD); Bianchi procedure; Postoperative complications

#### Affiliation:

Department of Pediatric Surgery, "Juan P. Garrahan" Pediatric National Hospital. Buenos Aires Autonomous City, Argentina

#### \*Corresponding author:

D'Alessandro PD, Department of Pediatric Surgery, "Juan P. Garrahan" Pediatric National Hospital. Buenos Aires Autonomous City, Argentina.

**Citation:** D'Alessandro PD, Rubio MA, Paz EGN, Takeda SC, Boglione MM, Barrenechea ME. Total Esophagogastric Dissociation for Refractory Gastroesophageal Reflux Disease: Preliminary Experience. Archives of Clinical and Biomedical Research. 10 (2026): 154-159.

**Received:** March 29, 2026

**Accepted:** April 06, 2026

**Published:** May 06, 2026

## Introduction

Neurologically impaired (NI) children present significant pharyngeal neuromuscular incoordination with swallowing difficulties leading to inadequate oral nutrition, recurrent aspiration pneumonitis and failure to thrive [1]. Severe gastroesophageal reflux is a common association and is often difficult to control. Nissen fundoplication with or without a feeding gastrostomy has been the traditional surgical approach in our center. However, fundoplication is not hassle-free with a consistent rate of recurrence.

Total esophagogastric dissociation (TEGD) is an alternative for antireflux redo surgery or as a primary option in selected cases in whom the failure of fundoplication is highly disruptive for patients' quality of life.

This paper seeks to present, in a descriptive way, our first experience on TEGD.

## Materials and Methods

An institutional retrospective observational database review was performed (REDCap 12.1.2 - © 2023 Vanderbilt University). All patients who underwent TEGD procedure were analysed. There weren't any exclusion criteria. Data collected on demographics, patients' diagnosis, neurological condition, previous medical history, whether TEGD was performed as a primary or secondary procedure and early and late surgical complications.

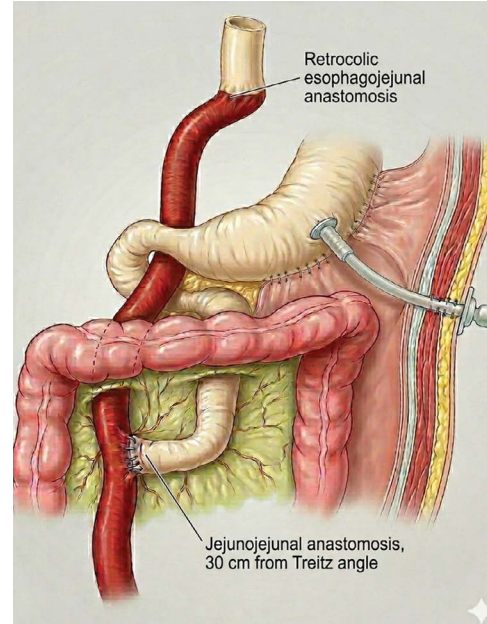
## Operative technique

Under general anesthesia supraumbilical midline abdominal incision, with retraction of the left lobe of the liver for access to the esophagogastric junction. Any residual fundoplication was taken down (if necessary), and the distal esophagus isolated. The esophagus was transected above the gastroesophageal junction, and the gastric end was oversewn. If possible, previous gastrostomy is preserved. A liberal isoperistaltic 20cm loop of jejunum was mobilized on a tension-free vascular pedicle. The loop was brought through the transverse mesocolon passing behind the stomach in Roux-en-Y fashion anastomose with the proximal esophagus. Bowel continuity was established by an end-to-side jejunum-jejunum anastomosis 15 cm from the ligament of Treitz. A digital pyloroplasty was performed to facilitate gastric emptying. The stomach was drained continuously postoperatively through the gastrostomy and the jejunum through a nasojejunal tube until return bowel activity (Figure 1).

## Results

Between 2007 and 2023, 18 children (11 male and 7 female) underwent TEGD (Table 1). Sixteen patients present GERD symptoms. Twelve children had severe neurological impairment (Gross Motor Function Grade V), 3 esophageal

atresia, 2 severe peptic stenosis (a patient with esophageal stenosis caused by portal hypertension), and one congenital diaphragmatic hernia.



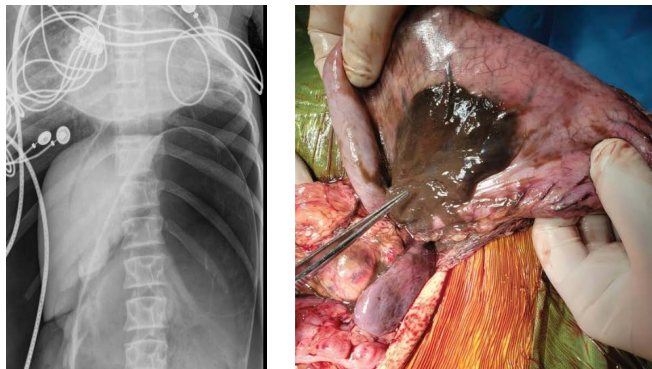
**Figure 1:** Schematic representation of the Total Esophagogastric Dissociation (TEGD) procedure. The diagram illustrates the distal esophageal transection, the Roux-en-Y jejunal limb interposition for esophago-jejunal anastomosis, and the maintenance of the gastric reservoir with a drainage gastrostomy and digital pyloroplasty.

**Table 1:** Patients conditions.

	n	%
<b>TEGD</b>	<b>18</b>	<b>100</b>
<b>Diagnosis</b>		
NI	12	
Esophageal Atresia	3	
Esophageal stenosis	2	
Congenital Diaphragmatic Hernia	1	
<b>GERD Group</b>		
<b>GERD Group</b>	<b>16</b>	<b>89%</b>
NI	11	
No NI	5	
Primary TEGD (p-TEGD)	5	
Secondary TEGD (s-TEGD)	11	
NI & p-TEGD	5	
No NI & p-TEGD	1	
Fundoplication Failure	11	
NI & Fundoplication Failure	7	
<b>NO-GERD Group</b>		
<b>NO-GERD Group</b>	<b>2</b>	<b>11%</b>
NI	1	
No NI	1	
p-TEGD	1	
s-TEGD	1	

Six children had a definitive primary TEGD (p-TEGD). Five had severe GERD symptoms. In those who were completely dependent on enteral tube feedings, had no oral intake; they were also nonambulatory and had severe neurologic impairment (n=4) primary TEGD was indicated. Fifth GERD patients had no neurological impairment and were presented with severe GERD because of portal hypertension with severe peptic stenosis. One neurological impairment (NI) child with no GERD presented an acute gastric volvulus, compromising totally gastric vitality.

Twelve secondary “rescue” procedures (s-TEGD) were done. Eleven patients present a previous Nissen fundoplication failure with recurrent GERD. Seven GERD patients were NI. In one no NI and no-GERD patient, who has an esophageal replacement with colon, severe gastroparesis with delayed gastric emptying and graft damage was treated with a modified TEGD (Figure 2).



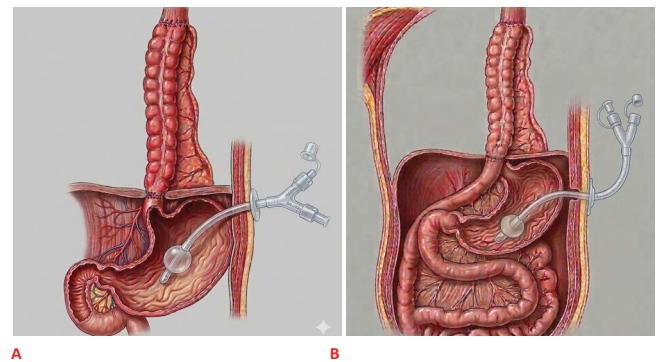
**Figure 2:** Pediatric patient with Ehlers-Danlos syndrome presenting to the emergency department with acute abdomen and signs of peritoneal irritation. (A) Plain abdominal radiograph demonstrating significant pneumoperitoneum. (B) Intraoperative finding of massive gastric necrosis resulting from an acute total gastric axial volvulus, illustrating the high-complexity scenarios encountered in this series.

The most frequent presenting features were vomiting (77,8%) and dysphagia (38,9%). Twelve patients had a preoperative endoscopy. Half of them present esophagitis according to Los Angeles classification: 4 patients were Los Angeles D. Five patients had a normal endoscopy, and one presented with several esophageal stenosis.

Seven early complications (first thirty postoperative days) were reported in six patients (33.3%). Five patients required surgery (83%): two bowel adhesion obstructions were solved by a laparotomy, one bowel perforation requiring an enterostomy, one anastomotic leakage needed a redo, a wound dehiscence and one esophagojejunal anastomotic stricture was dilated with an endoscopy balloon. The patient who did not receive surgery was a total gastric volvulus with extensive necrosis presented with a postoperative refractory septic shock non-related to the TEGD procedure.

Three patients presented late complications (16,6%). All

patients required surgery procedures. One of them presented pneumoperitoneum in x-rays, and laparotomy did not show signs of bowel perforation or anastomotic leakage; after an extensive abdominal cavity exploration without finding a cause of the pneumoperitoneum, a drain was placed. A second patient presented an extensive necrosis secondary to small bowel volvulus: laparotomy and drainage were placed (Figure 3). The patient died at postoperative time. The last patient had a wound pyogenic granuloma who needed a surgical wound toilette.

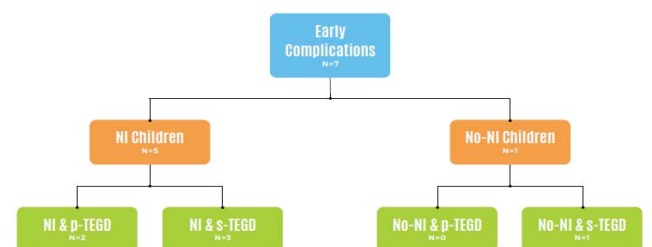


**Figure 3:** Modified TEGD in a complex esophageal replacement case. (A) Preoperative state of a patient with long-gap esophageal atresia previously treated with a colonic interposition graft. (B) Postoperative view following a modified TEGD performed to treat severe gastroparesis and reflux-induced damage to the colonic graft.

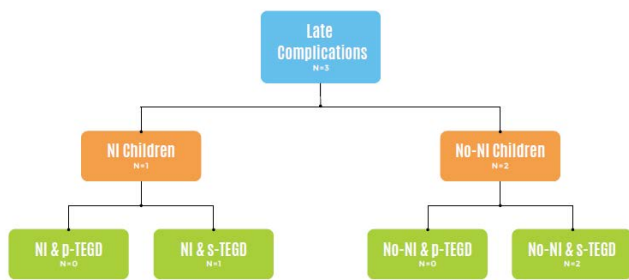
Early and Late complications were detailed in Figure 4 and 5.

Only two deaths (11%) were recorded. One related to TEGD procedure secondary to small bowel volvulus at late postoperative time.

On Follow-up all parents and caregivers referred to an improvement in quality of life after TEGD because there were no severe respiratory events, no frequent vomiting and an absence of GERD. Better feeding habits (12 patients with exclusive gastrostomy feeding and five with a normal oral intake) and weight gain were referred.



**Figure 4:** Distribution and classification of early postoperative complications. This diagram categorizes complications occurring within the first 30 days, highlighting that 83% of affected patients required surgical re-intervention for issues such as bowel obstruction and anastomotic leakage.



**Figure 5:** Analysis of late postoperative complications. The chart details morbidity occurring after the initial 30-day period, including small bowel volvulus and wound-related issues, which necessitated further surgical management.

## Discussion

NI children often present feeding problems because of esophageal dysmotility, reduced lower esophageal pressure, increased intra-abdominal pressure, and delayed gastric emptying.

Consequently, NI children have an increased risk of gastroesophageal reflux (GER).

Fundoplication has been the traditional surgical approach to this condition, but it is associated with a high failure rate of 6% to 25% [2] and persistence of unpleasant gastrointestinal symptoms. This high failure rate has been attributed, in NI children, to several factors such as gut dysmotility, seizure disorders, aerophagia, and central pain.

As described by Pearl et al. [3], the success ratio of the fundoplication is dependent on the neurologic status of the patient, and the major cause of fundoplication failure is the herniation of the wrap into the chest. Because of concomitant spasticity, convulsions, or scoliosis, the risk of herniation is high in NI children. One of the possible risk factors that induced failure of fundoplication is epilepsy [3].

In 1997, Bianchi [4] proposed TEGD as a “rescue” procedure for treating fundoplication failure because it eliminated the possibility of gastroesophageal reflux. In NI children severe GER is a common association and is often difficult to control. It may present symptomatically or silently, both carrying a high risk of damage. Bianchi has stressed the importance of “individualized therapy” tailored to each child’s specific needs.

Our first experience in the TEGD procedure started as a “rescue procedure” in Nissen fundoplication failure patients. Many severely neurologically (Gross Motor Function Grade V) affected patients do not have oral intake and are solely dependent on enteral tube feeding. In these patients we think that primary TEGD is a preventive measure before severe chronic respiratory failure becomes present and offers a definitive solution for GERD.

In our series there were 33,3% early complications and

16,6% late ones. We reported seven complications in six patients; 83% needed surgery. One patient presented an acute septic shock. Late complications all needed a surgical procedure to solve it.

Chhabra [5], et al reported 40 TEGD in a single institution. There were 16% early complications and 13% late complications. The reoperation rate in our cohort of children was 15,7%. In other series, Morabito et al. [6] did not report mortality and only 3 complications all needed surgery in 26 cases (11.5%). NI patients with recurrent GER may have repeated hospitalizations for pneumonia, failure to thrive, feeding intolerance, or gastric tube dysfunction [7].

We think that complication rate differences between this series and ours lie in a lack of experience in the first procedures (five major complications were on the first five TEGD procedures) concomitant to the surgical learning curve. Furthermore, in most cases complications occurred in rescue procedures. Also, one p-TEGD was in an acute gastric volvulus with a severe hemodynamic condition.

Coletta et al. [8] described 66 patients. Sixteen complications were reported: 9 early and 7 late. Rescue groups had a significant rate of complications compared to the primary TEGD. Primary TEGD mortality rate was 23,4% while mortality rate for rescue TEGD was 33%. Overall complication rate of 18.2% with a mortality attributable to the procedure of 1.5% [8]

The recurrence rate of antireflux procedures is higher, between 12% and 45%, and may be caused by wrap failure from repeated retching, gagging, and seizures. Redo fundoplication has a higher recurrence rate (25%) than initial operation as well as entailing a higher risk of complications [9].

Furthermore, it is important to consider that redo antireflux procedures often present significant technical challenges and suboptimal outcomes, positioning TEGD as a valuable alternative in the therapeutic spectrum.

Instead of the high rate of complications (10-30%) and a mortality attributable to TEGD procedure of almost 2% in different series, TEGD offers a 100% treatment for GERD and improves patients' quality of life. TEGD offers the advantage that by disconnecting the esophagus from the stomach, it eliminates all possibility of GER and also, by virtue of complete vagotomy at the time of operation, eliminates abnormal extrinsic innervation of the foregut. The combined pyloroplasty aids gastric emptying [2].

The primary objective of this study is to describe our initial institutional experience with TEGD and to report our preliminary outcomes, positioning it as a complementary alternative in the management of GERD. Our findings are intended to broaden the available treatment options rather

than advocate for the systematic over-indication of the procedure.

We acknowledge that a wide array of less invasive therapeutic options remains the standard of care for pediatric GERD: these range from optimized pharmacological regimens and specialized dietary protocols to the use of post-pyloric enteral nutrition—such as gastrojejunal (GJ) tubes—which effectively bypass the stomach to mitigate aspiration risks in complex patients [10]. However, in our experience, while these conservative and minimally invasive methods are valuable, they may prove insufficient for children with severe neurological impairment and intractable symptoms and for redo cases. In this specific cohort, we have found TEGD to be a robust, albeit aggressive, definitive solution for GERD but it's important to emphasize that TEGD is another additional therapeutic option for the management of GERD.

Current literature reviews on TEGD in NI children suggest statistically significant improvements in feeding tolerance, reduction of emetic symptoms, and overall patient comfort [9]. Regarding postoperative perceived qualitative clinical insights, our findings are based on structured parental and caregiver phone calls interviews. We acknowledge that the absence of a validated, disease-specific QoL instrument for this unique population represents a methodological limitation. However, the qualitative feedback was consistently positive; caregivers reported a perceived improvement in the children's daily well-being, with some advocating for the TEGD as a definitive management strategy for refractory GERD. Furthermore, improvements in feeding efficiency and subsequent weight gain were consistently noted by families.

NI children's parents must spend a lot of time and energy to cope with the needs of this fragile population. Feeding NI children is time consuming and requires long lasting meals to avoid GER as well as being a threat considering the high rates of aspiration and apnea. Therefore, TEGD not only improves NI children's clinical conditions and consequently the perceived qualitative clinical insights also can even reduce caregivers' stress and anxiety with positive repercussions on the entire family [11].

Due to the exceptional nature of TEGD as a procedure and the highly specific patient population (primarily for those with severe neurological impairment and failed anti-reflux surgeries), our cohort size is inherently limited. Consequently, a formal comparative statistical analysis was deferred in favor of a detailed descriptive study. Performing inferential statistics on a small, non-representative sample would increase the risk of Type II errors and generate potentially biased conclusions that lack external validity [12].

Furthermore, the complication rates observed in this series—while significant—are consistent with the high morbidity profiles reported in specialized literature. The complexity of TEGD, combined with the low annual caseload

for such a specialized technique, results in a protracted surgical learning curve. As noted in the Bianchi procedure's historical outcomes, the rarity of the indication limits the speed of technical consolidation, a factor that directly influences perioperative outcomes and remains a challenge even in high-volume tertiary centers [2,10].

## Conclusions

As well as Bianchi has stressed the importance of “individualized therapy” tailored to each child's specific needs, our initial institutional experience indicates that TEGD serves as a robust and definitive anatomical barrier against gastroesophageal reflux in a highly specific pediatric cohort. It is essential to emphasize that this study is a descriptive report of our preliminary outcomes and not a comparative analysis designed to establish TEGD as a superior technique over traditional antireflux procedures. Due to the inherent complexity of the procedure and the significant associated morbidity, TEGD should be viewed as a complementary tool within the therapeutic spectrum, intended to supplement rather than replace established clinical approaches. While it offers high clinical success in eliminating reflux and improving the quality of life for NI children when traditional methods fail, its indication must remain individualized. Since the procedure is not exempt from significant complications, it is fundamental to provide comprehensive preoperative counseling to families, clearly explaining all potential risks and benefits.

## References

1. Dall'Oglio L, Gatti C, Villa M, et al. A new and successful chance in surgical treatment of gastroesophageal reflux in severely neurologically impaired children: Bianchi's procedure. *Eur J Pediatr Surg* 10 (2000): 354-359.
2. Goyal A, Khalil B, Choo K, et al. Esophagogastric dissociation in the neurologically impaired: an alternative to fundoplication? *J Pediatr Surg* 40 (2005): 915-918.
3. Lauriti G, Lisi G, Lelli Chiesa P, et al. Gastroesophageal reflux in children with neurologically impairment: a systematic review and meta-analysis. *Pediatr Surg Int* 34 (2018): 1139-1149.
4. Bianchi A. Total esophagogastric dissociation: an alternative approach. *J Pediatr Surg* 32 (1997): 1291-1294.
5. Chhabra S, Nedeja AM, Kauffman L, et al. Total esophagogastric dissociation: single center experience. *J Pediatr Surg* 52 (2017): 260-263.
6. Morabito A, Lall A, Lo Piccolo R, et al. Total esophagogastric dissociation: 10 years' review. *J Pediatr Surg* 41 (2006): 919-922.
7. Coletta R, Aldeiri B, Jackson R, et al. Total esophagogastric

- dissociation: lessons from two decades of experience. *J Pediatr Surg* 54 (2019): 1214-1219.
8. Islam S, Teitelbaum DH, Buntain WL, et al. Esophagogastric separation for failed fundoplication in neurologically impaired children. *J Pediatr Surg* 39 (2004): 287-291.
  9. Peters RT, Goh YL, Veitch JM, et al. Morbidity and mortality in total esophagogastric dissociation: a systematic review. *J Pediatr Surg* 48 (2013): 707-712.
  10. Mirani Y, Roy YJ, John T. Comparative analysis of pharmacological treatments and lifestyle modifications for managing gastroesophageal reflux disease in infants: a literature review. *Br J Hosp Med (Lond)* 86 (2025): 1-10.
  11. Parente G, Cravano SM, Di Mitri M, et al. Total esophagogastric dissociation (TEGD) in neurologically impaired children: the floor to parents. *Updates Surg* 74 (2022): 1881-1887.
  12. Griggs RC, Batshaw M, Dunkle M, et al. Clinical research for rare disease: opportunities, challenges, and solutions. *Mol Genet Metab* 96 (2009): 20-26.



This article is an open access article distributed under the terms and conditions of the [Creative Commons Attribution \(CC-BY\) license 4.0](https://creativecommons.org/licenses/by/4.0/)