

Autologous Platelet-Rich Plasma Concentrate as an Adjunct to Autologous Retinal Transplant for Large Post-Traumatic Macular Holes Results in Favorable Anatomical and Visual Outcomes: A Case Report

Ogugua Ndubuisi Okonkwo^{1*}, Alice Cecilia Elsie Taylor², Adekunle Olubola Hassan¹, Idris Oyekunle¹, Lateefat Oshunkoya¹, Adewale Ishola¹

Abstract

Purpose: Report spontaneous closure of residual eccentric defect following autologous retinal transplant (ART) and adjunct autologous platelet-rich plasma concentrate (PRPC) for a large post-traumatic macular hole (MH), with an unusual improvement in vision after silicone oil removal (SOR).

Case description: A 14-year-old male of African descent suffered OD blunt trauma from a projectile, resulting in a large (1200 microns) full-thickness MH. He underwent vitrectomy and ART. At the end of surgery, after fluid-air exchange, three drops of PRPC were added to the ART before silicone oil injection. He had silicone oil removed four weeks post-operation with an air-filled vitreous cavity.

Outcome: A notable host-donor eccentric edge defect was observed on OCT day one after ART surgery. The defect was expected to widen with postoperative graft retraction. However, the defect closed spontaneously, seen on OCT one week after surgery. Additionally, two months after SOR, vision improved significantly from 6/36 (20/120) to 6/12 (20/40), N10 unaided. He remains phakic, and no side effects from PRPC were observed. OCT Angiography showed vascularization of the donor graft.

Conclusion: This report on ART with adjunctive PRPC shows a positive outcome. We believe PRPC significantly contributed to the uncommon closure of the eccentric defect and the good visual results. Further research on PRPC is needed to explore its potential cellular rejuvenation and fibrin effects in ART, which might result in it becoming standard practice. Larger prospective studies that combine ART and PRPC could provide stronger evidence to validate this method.

Keywords: Platelet rich plasma concentrate; Macular hole; Trauma; Autologous retina transplant; Vitrectomy.

Introduction

Macular holes are now successfully managed with good anatomical and visual outcomes. High success rates and favorable visual prognosis are reported for small and medium-sized idiopathic macular holes with a minimum diameter of < 500 microns on optical coherence tomography (OCT) [1]. In macular holes with larger diameters, because outcomes are less predictable with conventional surgery, several techniques have been described to plug the large macular hole and achieve macular hole closure, including the use of lens capsule, internal limiting membrane plug, autologous retina transplant, and amniotic membrane graft [2-5]. Impressive

Affiliation:

¹Department of Ophthalmology, Eye Foundation Hospital & Eye Foundation Retina Institute, Lagos, Nigeria

²Department of Ophthalmology, University of Sierra Leone Teaching Hospitals Complex, Freetown, Sierra Leone

*Corresponding Author

Prof. Ogugua Ndubuisi Okonkwo, Eye Foundation Hospital, 27 Isaac John Street, GRA. Ikeja, Lagos, Nigeria

Citation: Ogugua Ndubuisi Okonkwo, Alice Cecilia Elsie Taylor, Adekunle Olubola Hassan, Idris Oyekunle, Lateefat Oshunkoya, Adewale Ishola. Autologous Platelet-Rich Plasma Concentrate as an Adjunct to Autologous Retinal Transplant for Large Post-Traumatic Macular Holes Results in Favorable Anatomical and Visual Outcomes: A Case Report. Archives of Clinical and Medical Case Reports. 10 (2026): 73-77.

Received: March 10, 2026

Accepted: March 17, 2026

Published: March 27, 2026

visual outcomes have been reported with these techniques for the treatment of large macular holes [3]. Recently, there has been a growing interest in using platelet-rich plasma concentrate (PRPC) for the surgical treatment of macular holes [6-7]. PRPC alone has been applied to the macular hole and used as an adjunct to other surgical techniques, including internal limiting membrane peel, inverted internal limiting membrane flap, and amniotic membrane techniques [8]. Reports suggest good anatomical outcomes following the use of PRPC in large and refractory MHs [9]. Aside from good anatomical and functional outcomes following PRPC use, one study demonstrated that the foveal avascular zone reduced significantly [10].

Shpak et al. demonstrated the superiority of adjuvant autologous PRPC over conventional internal limiting membrane peel alone [11]. Shpak reported a higher macular hole closure rate in larger macular holes and better vision in PRPC eyes compared to control eyes. Several positive reviews of PRPC for treating macular holes have fueled its increasing use.

Following the global consortium's paper on the effectiveness and favorable outcome of autologous retina transplant to close large, refractory macular holes [12], surgeons have shared their results with this technique, incorporating significant modifications. We present the outcome of autologous retina transplant (ART) combined with autologous platelet-rich plasma concentrate (PRPC) for a large post-traumatic macular hole. Although some studies have used whole blood as an adhesive with ART, our literature review did not find a report using adjuvant autologous PRPC with ART. The patient and his mother gave written informed consent for publishing his case report and images. The study was conducted in accordance with the principles of the Declaration of Helsinki and was approved by the Eye Foundation Health Research Ethics Committee.

Case Report and Surgical Technique

A 14-year-old male of African descent presented in November 2024, complaining of a sudden reduction in vision in his right eye over the past three months following a projectile injury to that eye. He reported no significant past ocular or medical history. His mother has glaucoma. His overall health was good at the time of the visit. The key finding on examination was a visual acuity of 6/36 (20/120) in the right eye. Intraocular pressure was 12 mmHg in the right eye. The anterior segment appeared normal. On dilated funduscopy, a large full-thickness retina defect centered on the fovea was observed. Further assessment with spectral-domain optical coherence tomography (SD-OCT) confirmed a macular hole with a minimum diameter of 1200 microns (Figure 1). The left eye was normal, with a visual acuity of 6/6 (20/20).

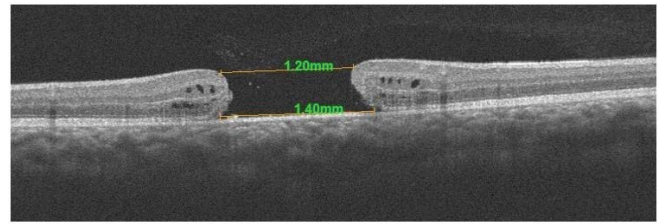


Figure 1: Spectral-domain optical coherence tomography (SD-OCT) confirmed a macular hole measuring 1200 microns in minimum diameter, with a visual acuity of 6/36 (20/120).

Given the large size of the macular hole, an autologous retinal transplant (ART) was considered an appropriate option for closure. Due to the hole's post-traumatic nature, duration, and size, the patient and his mother were informed of the guarded prognosis for any potential improvement in vision. Both the mother and the patient provided informed consent and assent for the surgery, respectively. Four days after the initial clinic evaluation, the surgery was performed under general anesthesia.

A three-port pars plana technique was used. During surgery, the attached posterior vitreous was detached, and retinal graft tissue was harvested from the superiotemporal retina, anterior to the superotemporal vascular arcade. First, a drop of freshly prepared autologous PRPC (created from blood taken during anesthesia induction) was applied to the macular hole. Placing the harvested neurosensory retina graft on the PRPC-covered macular hole caused the graft to stiffen, become rigid, and contract. The retina graft appeared smaller and could not be manipulated to cover the macular hole. Therefore, this graft tissue was removed from the macular hole and discarded. A new graft was harvested from an area of the retina adjacent to the previous site. The neurosensory retina graft was excised using straight intraocular scissors. It was moved with Eckardt forceps, using a gentle pinch technique to grasp the center of the graft from the harvest bed and positioned onto the macular hole covered with perfluorocarbon liquid. Care was taken to avoid dragging the graft over the retina. The graft was carefully spread open with forceps to cover the macular hole. Next, fluid-air exchange was performed, with gentle aspiration nasal to the disc until all vitreous fluid was removed. Then, three drops of freshly prepared PRPC were applied to the macula to cover both the graft and the macular area. Silicone oil (1000CS) was injected into the vitreous cavity. The sclerostomies were closed with eight-zero Vicryl. The procedure was performed by an experienced vitreoretinal surgeon (ONO). The patient was examined on the first day, after one week, and one month following surgery. A macular OCT and OCT-Angiography were performed at each visit. Silicone oil was removed without difficulty four weeks after surgery. Stable graft tissue remained within the macular hole, and air-fluid exchange was completed at the end of the procedure, leaving an air-filled vitreous cavity.

Technique for Preparation of Autologous Platelet-Rich Plasma Concentrate

Use a sterile technique with a face mask and sterile gloves.

Blood collection

Withdraw 3 – 5 cc of the patient's venous blood (at entry to the operating room) into a sterile test tube containing anticoagulant lithium heparin.

Centrifugation

Two circles of centrifugation are done to separate the blood components into three layers: red blood cells, platelet-poor plasma (PPP), and platelet-rich plasma (PRP)

- a) **First centrifugation:** For the first time, spin the whole blood sample for 15 minutes at 3000 RPM. Using a sterile pipette, transfer the plasma into a plain sterile bottle.
- b) **Second centrifugation:** Spin the collected plasma for another 15 minutes at 3000 rpm. Then, pipette the PRP into a sterile bottle.

Results and Outcomes of Surgery

On the first postoperative day, the macular hole was closed post-ART OCT (Figure 2). An eccentric defect was present at the temporal border of the macular hole (Figure 2). Within this defect was hyper-reflective material, most likely fibrin from PRPC (Figure 2, yellow arrow).

The defect closed during the first postoperative week, as seen on OCT (Figure 3).

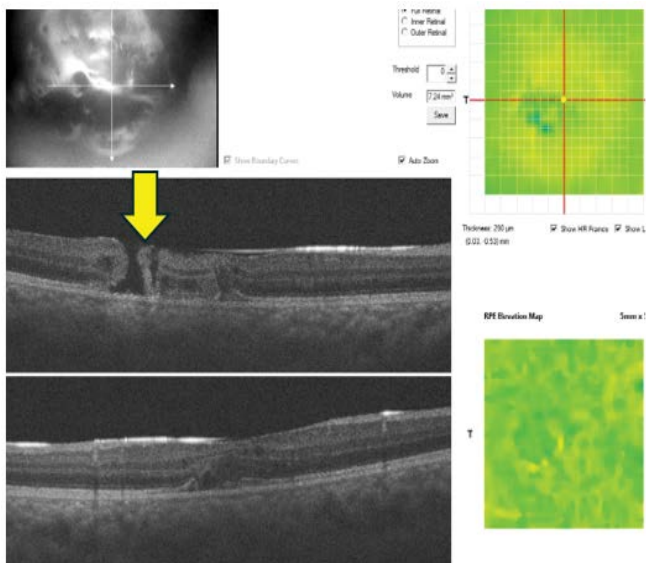


Figure 2: The first postoperative day displays ART within the macular hole and an eccentric macular defect. A hyperreflective material is visible within the eccentric defect, likely fibrinous from the PRPC.

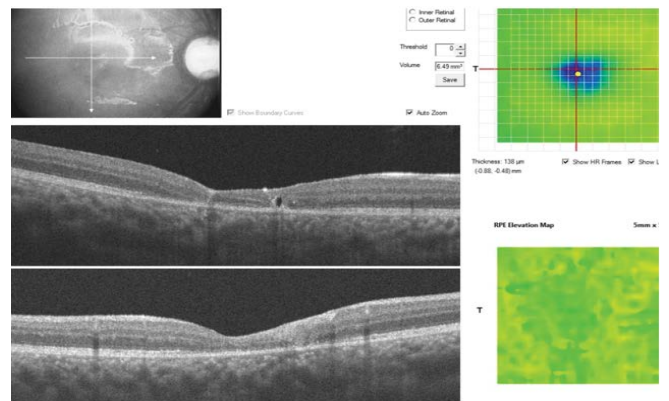


Figure 3: Eccentric macular defect is closed on OCT at 1-week post-surgery.

Hole closure persisted on pre-SOR OCT, performed at 4 weeks. One week after SOR, following air absorption, the macular hole remained closed (Figure 4 showing progression from pre-operation to a week after SOR), and the external limiting membrane and IS/OS were evident.

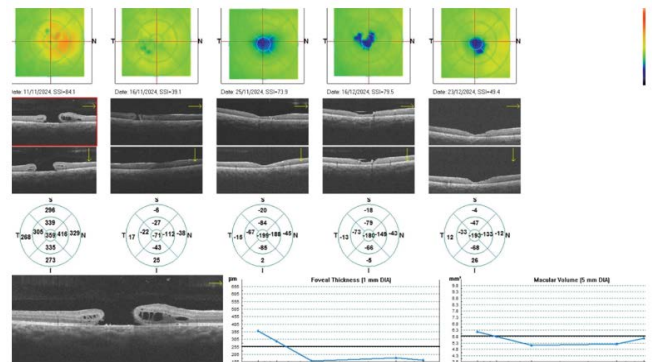


Figure 4: Persistently closed macular hole on progressive OCT taken from the first week till 4 weeks after surgery.

OCT Angiography at this visit revealed temporal and inferior vascularization of the graft in the superficial and deep capillary plexi (Figure 5).

On OCT, ELM and IS/OS were present at three months postoperative (Figure 6, yellow arrow).

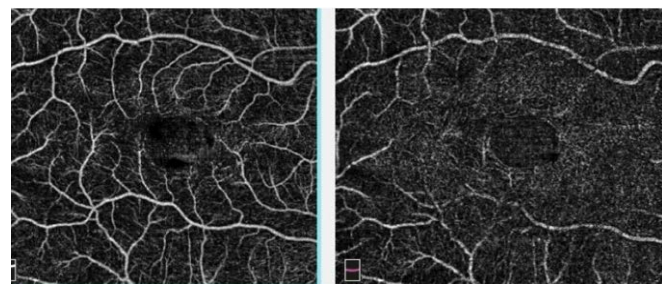


Figure 5: OCT Angiography revealed temporal and inferior vascularization of the graft in the superficial and deep capillary plexi.

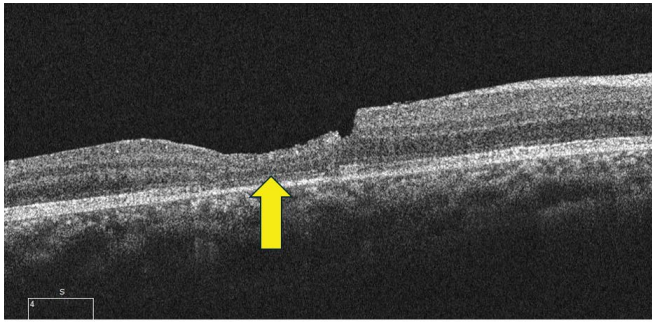


Figure 6: OCT showing the appearance of ELM and IS/OS present at three months postoperative.

Visual acuity steadily improved from a pre-operative measure of 6/36 (20/120) to 6/12 (20/40) and N10 (unaided) at three months post SOR. The patient remains phakic, and initial postoperative increases in IOP were managed using topical ocular hypotensives.

Discussion

We report remarkably positive anatomical and visual results after ART combined with adjuvant PRPC. The most notable outcome was the closure of the residual eccentric defect in the macular hole, which was observed to occur just one day after ART. Based on the author's previous experience with ART, graft tissue typically retracts days post-surgery, often causing the graft edge to move toward the center and widening any eccentric defect or gap between the retinal graft and the host tissue. Our goal was to address this issue during silicone oil removal. However, unexpectedly, the graft was in contact with and joined the host retinal edge at the one-week evaluation. We believe that the platelet concentrate was essential for this closure. OCT revealed an opaque, hyperreflective tissue, likely fibrin from the PRPC, within the defect. This tissue was trapped by the silicone oil and remained in the eccentric macular hole. The surgeon has observed similar persistent edge defects in several ART cases but has never seen such edge apposition in either the short or long term, as in this case.

Furthermore, a multicenter study on ART reported eccentric defects in 10% of all macular holes and 26% of macular hole retinal detachments. This suggests that eccentric defects are common occurrences after ART. In our initial ART experience, we reported graft retraction in two of three eyes. The use of PRPC could be a solution for this relatively frequent occurrence of post-ART eccentric defects. The hyperreflective material on SD-OCT that appeared trapped within the defect by the silicone oil (Figure 2) is rich in platelets and fibrin, and likely responsible for the subsequent apposition of the tissue edges and closure of the defect. We have also used isolated PRPC in our service to close macular holes associated with rhegmatogenous retinal detachment, achieving good anatomical apposition of the macular hole

edges. Other authors report PRPC and gas as treatments for persistent macular holes, supporting our findings for PRPC use.

The second notable finding was a significant and unexpected improvement in the patient's vision. Vision steadily improved from 6/36 to 6/9 (N10) over 12 weeks following ART surgery and SOR. Such an improvement has not been seen in other large macular holes treated with ART at the author's clinic. The macular hole was large, had existed for three months, and had unfavorable prognostic factors. We believe that the use of PRPC influenced his vision. Additionally, OCT showed the preservation of the outer retina graft tissue, and OCTA revealed graft vascularization.

Two grafts were harvested from this patient. The first was placed over the macular hole after drops of PRPC had been applied to the bare foveal RPE. The ART immediately became stiff, no longer malleable, and could not be unfolded to fill the macular hole. This tissue rigidity was caused by the enhanced clotting action induced by the pre-placement of PRPC. This piece of retinal tissue was discarded. The second piece was harvested and placed in the MH. This time, the PRPC was applied over the graft in an air-filled eye before silicone oil was injected. The recipient site RPE and donor tissue photoreceptors had contacted the PRPC. We believe that the PRPC produces pro-cellular rejuvenating factors that promote the health and optimal function of both RPE and photoreceptors, potentially leading to better visual acuity. In summary, PRPC activated RPE and photoreceptors, improving cell function and recovery over 4 months. Based on our experience with this case, we recommend that PRPC be placed on the ART graft after the graft tissue is positioned in the fovea bed, rather than on the bare fovea before graft placement. Some authors have reported placing whole blood on the bare foveal RPE as an adhesive before placing the graft tissue [13,17]. This practice allows the whole blood to act as an adhesive but cannot be applied with PRPC. The platelet concentration in PRPC exceeds that in whole blood. As seen in our report, high platelet concentration quickly causes tissue stiffening due to clotting, making it challenging to unfold the graft and place it uniformly within the macular hole. Furthermore, subretinal hemoglobin in whole blood may damage RPE cells, raising concerns about potential toxicity [18].

Conclusion

This report on surgical technique and outcome is retrospective and a single-case report, and therefore not generalizable. It is possible that the patient's young age contributed to the favorable outcome. According to several reports, PRPC appears to have a proven beneficial effect in macular hole surgery. In ART, it can positively affect the closure of the residual eccentric defect and improve

the survival of both RPE and transplanted photoreceptors. Moreover, PRPC contains negligible hemoglobin; therefore, RPE toxicity from iron in hemoglobin is not a significant concern compared to the use of whole blood. This feature improves PRPC's safety. We recommend further studies on this promising technique as an intraoperative adjuvant for ART to seal a would-be eccentric defect and improve graft survival and function with improved vision.

Acknowledgements

There is no one to be acknowledged for this work

Funding

No external source of funding was received.

Conflicts of Interest

None of the authors has a relevant financial interest.

References

1. Yamashita T, Sakamoto T, Terasaki H, et al. Best surgical technique and outcomes for large macular holes: retrospective multicentre study in Japan. *Acta Ophthalmol* 96 (2018): 904-910.
2. Arda H, Maier M, Schultheiß M, et al. Advances in management strategies for large and persistent macular hole: An update. *Surv Ophthalmol* 69 (2024): 539-546.
3. Rezende FA, Ferreira BG, Rampakakis E, et al. Surgical classification for large macular hole: based on different surgical techniques results: the CLOSE study group. *Int J Retina Vitreous* 9 (2023): 4.
4. Felfeli T, Corrin M, Papanikolaou J, et al. Macular Hole Hydrodissection Technique with Human Amniotic Membrane for Repair of Large Macular Holes. *Retin Cases Brief Rep* 17 (2023): 767-770.
5. Khaqan HA, Sahyoun JY, Haider MA, et al. Amniotic Membrane Graft for the Treatment of Large Refractory Macular Hole. *Retina* 42 (2022): 1479-1483.
6. Parisi G, Gelormini F, Ricardi F, et al. Platelet rich plasma for primary macular hole: A case series. *Eur J Ophthalmol* 34 (2024): 1984-1990.
7. Arias JD, Hoyos AT, Alcántara B, et al. Plasma Rich in Growth Factors for Persistent Macular Hole: A Pilot Study. *Retin Cases Brief Rep* 16 (2022): 155-160.
8. Kapoor KG, Khan AN, Tieu BC, et al. Revisiting autologous platelets as an adjuvant in macular hole repair: chronic macular holes without prone positioning. *Ophthalmic Surg Lasers Imaging* 43 (2012): 291-295.
9. Coca M, Makkouk F, Picciani R, et al. Chronic Traumatic Giant Macular Hole Repair with Autologous Platelets. *Cureus* 9 (2017): e955.
10. Yang N, Zeng S, Yang J, et al. Application of Platelet-Rich Fibrin Transplantation for Large Macular Hole. *Curr Eye Res* 47 (2022): 770-776.
11. Shpak AA, Shkvorchenko DO, Krupina EA. Surgical treatment of macular holes with and without the use of autologous platelet-rich plasma. *Int Ophthalmol* 41 (2021): 1043-1052.
12. Moysidis SN, Koulisis N, Adrean SD, et al. Autologous Retinal Transplantation for Primary and Refractory Macular Holes and Macular Hole Retinal Detachments: The Global Consortium. *Ophthalmology* 128 (2021): 672-685.
13. Liu PK, Chang YC, Wu WC. Management of refractory macular hole with blood and gas-assisted autologous neurosensory retinal free flap transplantation: a case report. *BMC Ophthalmol* 18 (2018): 230.
14. Wu AL, Chuang LH, Wang NK, et al. Refractory macular hole repaired by autologous retinal graft and blood clot. *BMC Ophthalmol* 18 (2018): 213.
15. Okonkwo ON, Hassan AO, Akanbi T. Autologous Neurosensory Retinal Transplantation: A Report of Three Cases. *J Ophthalmic Vis Res* 16 (2021): 68-76.
16. Schaub F, Gözlügöl N, von Goscinski C, et al. Outcome of autologous platelet concentrate, and gas tamponade compared to heavy silicone oil tamponade in persistent macular hole surgery. *Eur J Ophthalmol* 31 (2021): 664-672.
17. Chang YC, Liu PK, Kao TE, et al. Management of Refractory Large Macular Hole with Autologous Neurosensory Retinal Free Flap Transplantation. *Retina* 40 (2020): 2134-2139.
18. Muramatsu A, Nakamura S, Hirayama T, et al. Both hemoglobin and hemin cause damage to retinal pigment epithelium through the iron ion accumulation. *J Pharmacol Sci* 155 (2024): 44-51.



This article is an open access article distributed under the terms and conditions of the [Creative Commons Attribution \(CC-BY\) license 4.0](https://creativecommons.org/licenses/by/4.0/)